

Medicine Clerkship
Weill Medical College of Cornell University
Final Examination Sample Questions

Instructions

1. For each question, choose the one best answer
 2. Write the answer on the answer sheet
 3. Please hand in both the questions and the answer sheet at the end of the exam
 4. Please do not discuss the examination with others
-
1. A 58 year-old man comes to the emergency department because of dyspnea. The arterial blood gas is as follows: pH 7.50, PCO₂ 55, PO₂ 90. Which of the following is the predominant acid-base disorder?
 - A. Metabolic acidosis
 - B. Metabolic alkalosis
 - C. Respiratory acidosis
 - D. Respiratory alkalosis

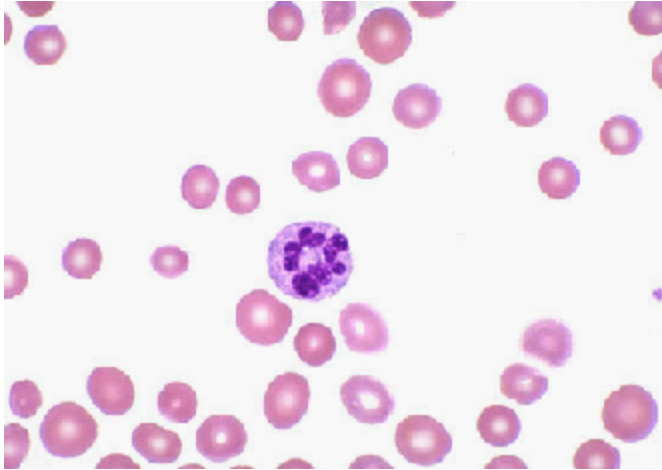
 2. A 25 year-old man has had 8 weeks of crampy abdominal pain, bloody bowel movements, rectal urgency, 12 pound weight loss, and joint pain. The patient is clinically stable. Which of the following tests is indicated first?
 - A. Abdominal CT scan
 - B. Abdominal MRI scan
 - C. Abdominal sonogram
 - D. Barium enema
 - E. Bleeding scan
 - F. Colonoscopy
 - G. Meckel's scan
 - H. Upper GI series

 3. A 68 year-old man, previously well, is admitted to the hospital because of fever and cough for the past 3 days. The temperature is 39°C (tympanic). Coarse crackles are heard throughout the left lower lung field. Chest X-ray shows a dense infiltrate of the left lower lobe. Which of the following is the best choice of antibiotics?
 - A. Cefuroxime and azithromycin
 - B. Ciprofloxacin
 - C. Erythromycin
 - D. Isoniazid with rifampin, ethambutol, and pyrazinamide
 - E. Penicillin

 4. A 68 year-old woman is admitted to the hospital because of fatigue for 3 months. Her admission CBC shows the following:

<u>Test</u>	<u>Patient value</u>	<u>Normal value</u>
Hemoglobin	7.5	14-18 g/dL
WBC	6.3	3.4-11.2 K/uL
MCV	110	81-100 fl
Reticulocyte platelet	1%	1-2%
	100	150-450 K/uL

The peripheral smear is shown below.



Which of the following is the most likely cause of her anemia?

- A. Acute myelogenous leukemia
- B. Anemia of chronic disease
- C. Beta thalassemia minor
- D. Iron deficiency anemia
- E. Pernicious anemia

5. A 60 year-old woman is brought to the emergency room because of severe chest pain for the past 1 hour. The past medical history is notable for hypertension for 15 years. The blood pressure is 106/70 mm Hg, and the heart rate is 104 /min. Examination shows clear lungs, jugular venous pressure 12 cm water; and hepatojugular reflux. EKG shows left bundle branch block, unchanged from prior tracings. Troponin I is elevated. Which of the following is the most likely diagnosis?

- A. Myocardial infarction of the anterior wall of the left ventricle
- B. Myocardial infarction of the inferior wall of the left ventricle
- C. Myocardial infarction of the lateral wall of the left ventricle
- D. Myocardial infarction of the posterior wall of the left ventricle
- E. Myocardial infarction of the right ventricle

Answers to questions

1. **B.** In interpreting an ABG, first look at the pH. pH < 7.40 indicates acidemia, pH > 7.40 indicates alkalemia. Next, look at the pCO₂. In a patient with alkalosis, PCO₂ < 40 mm Hg indicates respiratory alkalosis; the patient is increasing elimination of acid in the form of CO₂. PCO₂ > 40 mm Hg indicates metabolic alkalosis; the patient is decreasing elimination of acid in order to compensate for the metabolic problem.
2. **F.** The patient's clinical presentation is characteristic of ulcerative colitis. The diagnostic test of choice for UC is colonoscopy. Abdominal imaging has no role at this point. In any event, colonoscopy is indicated for persons with rectal bleeding.
3. **A.** In an older adult with community-acquired pneumonia, the most common causative organisms are *Pneumococcus pneumoniae*, *Hemophilus influenzae*, *Mycoplasma pneumoniae*, *Chlamydia pneumoniae*, and *Legionella pneumophila*. To cover these organisms, recommended regimens include (i) 2nd or 3rd generation cephalosporin, plus macrolide, or (ii) Pneumococcal-specific fluoroquinolone. Of the possible answers, only A meets these criteria. Note that ciprofloxacin has inadequate coverage of *Pneumococcus*. This patient's clinical presentation is classic for Pneumococcal pneumonia.
4. **E.** The CBC shows severe anemia with high MCV. The WBC is normal. The platelet count is mildly decreased. The peripheral smear shows a mixed population of normal RBC and large RBC. In the center is a hypersegmented polymorphonucleocyte. Platelets are diminished. Together, these findings indicate megaloblastic anemia. Of the possible answers, only pernicious anemia causes megaloblastic anemia. The absence of Intrinsic Factor renders the patient unable to absorb Vitamin B12.
5. **E.** The clinical presentation is classic for myocardial infarction, corroborated by the elevated Troponin I. LBBB prevents EKG diagnosis of myocardial ischemia. However, the patient has signs of right heart failure (JVD, hepatomegaly) without signs of left heart failure (rales, S3 gallop.) Of the possible answers, only right ventricular infarction can cause RV failure without LV failure.